

The Physiological Basis of the Electrocardiogram

Andrew T. Reisner, Gari D. Clifford, and Roger G. Mark

Before attempting any signal processing of the electrocardiogram it is important to first understand the physiological basis of the ECG, to review measurement conventions of the standard ECG, and to review how a clinician uses the ECG for patient care. The material and figures in this chapter are taken from [1, 2], to which the reader is referred for a more detailed overview of this subject. Further information can also be found in the reading list given at the end of this chapter.

The heart is comprised of muscle (*myocardium*) that is rhythmically driven to contract and hence drive the circulation of blood throughout the body. Before every normal heartbeat, or *systole*,¹ a wave of electrical current passes through the entire heart, which triggers myocardial contraction. The pattern of electrical propagation is not random, but spreads over the structure of the heart in a coordinated pattern which leads to an effective, coordinated systole. This results in a measurable change in potential difference on the body surface of the subject. The resultant amplified (and filtered) signal is known as an electrocardiogram (ECG, or sometimes EKG). A broad number of factors affect the ECG, including abnormalities of cardiac conducting fibers, metabolic abnormalities (including a lack of oxygen, or *ischemia*) of the myocardium, and macroscopic abnormalities of the normal geometry of the heart. ECG analysis is a routine part of any complete medical evaluation, due to the heart's essential role in human health and disease, and the relative ease of recording and analyzing the ECG in a noninvasive manner.

Understanding the basis of a normal ECG requires appreciation of four phenomena: the electrophysiology of a single cell, how the wave of electrical current propagates through myocardium, the physiology of the specific structures of the heart through which the electrical wave travels, and last how that leads to a measurable signal on the surface of the body, producing the normal ECG.

1.1 Cellular Processes That Underlie the ECG

Each mechanical heartbeat is triggered by an *action potential* which originates from a rhythmic pacemaker within the heart and is conducted rapidly throughout the organ to produce a coordinated contraction. As with other electrically active tissues

1. Diastole, the opposite of systole, is defined to be the period of relaxation and expansion of the heart chambers between two contractions, when the heart fills with blood.

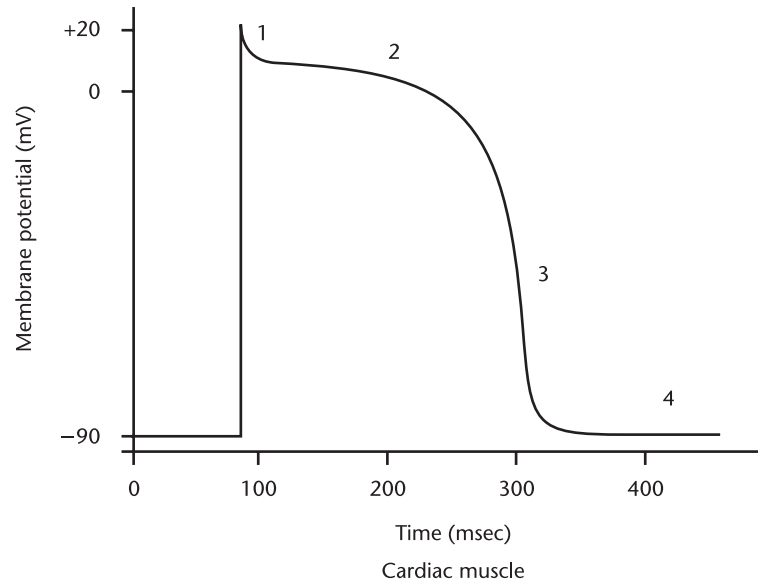


Figure 1.1 A typical action potential from a ventricular myocardial cell. Phases 0 through 4 are marked. (From: [2]. © 2004 MIT OCW. Reprinted with permission.)

(e.g., nerves and skeletal muscle), the myocardial cell at rest has a typical transmembrane potential, V_m , of about -80 to -90 mV with respect to surrounding extracellular fluid.² The cell membrane controls permeability to a number of ions, including sodium, potassium, calcium, and chloride. These ions pass across the membrane through specific ion channels that can open (become activated) and close (become inactivated). These channels are therefore said to be *gated* channels and their opening and closing can occur in response to voltage changes (voltage gated channels) or through the activation of receptors (receptor gated channels).

The variation of membrane conductance due to the opening and closing of ion channels generates changes in the transmembrane (action) potential over time. The time course of this potential as it depolarizes and repolarizes is illustrated for a ventricular cell in Figure 1.1, with the five conventional phases (0 through 4) marked. When cardiac cells are depolarized to a *threshold* voltage of about -70 mV (e.g., by another conducted action potential), there is a rapid depolarization (phase 0 — the rapid upstroke of the action potential) that is caused by a transient increase in fast sodium channel conductance. Phase 1 represents an initial repolarization that is caused by the opening of a potassium channel. During phase 2 there is an approximate balance between inward-going calcium current and outward-going potassium current, causing a plateau in the action potential and a delay in repolarization. This inward calcium movement is through long-lasting calcium channels that open up when the membrane potential depolarizes to about -40 mV. Repolarization (phase 3) is a complex process and several mechanisms are thought to be important. The potassium conductance increases, tending to repolarize the cell via a potassium-mediated outward current. In addition, there is a time-dependent

2. Cardiac potentials may be recorded by means of microelectrodes.

decrease in calcium conductivity which also contributes to cellular repolarization. Phase 4, the resting condition, is characterized by open potassium channels and the negative transmembrane potential. After phase 0, there are a parallel set of cellular and molecular processes known as *excitation-contraction coupling*: the cell's depolarization leads to high intracellular calcium concentrations, which in turn unlocks the energy-dependent contraction apparatus of the cell (through a conformational change of the troponin protein complex).

Before the action potential is propagated, it must be initiated by *pacemakers*, cardiac cells that possess the property of *automaticity*. That is, they have the ability to spontaneously depolarize, and so function as pacemaker cells for the rest of the heart. Such cells are found in the sino-atrial node (*SA node*), in the atrio-ventricular node (*AV node*) and in certain specialized conduction systems within the atria and ventricles.³ In automatic cells, the resting (phase 4) potential is not stable, but shows spontaneous depolarization: its transmembrane potential slowly increases toward zero due to a trickle of sodium and calcium ions entering through the pacemaker cell's specialized ion channels. When the cell's potential reaches a threshold level, the cell develops an action potential, similar to the phase 0 described above, but mediated by calcium exchange at a much slower rate. Following the action potential, the membrane potential returns to the resting level and the cycle repeats. There are graded levels of automaticity in the heart. The intrinsic rate of the SA node is highest (about 60 to 100 beats per minute), followed by the AV node (about 40 to 50 beats per minute), then the ventricular muscle (about 20 to 40 beats per minute). Under normal operating conditions, the SA node determines heart rate, the lower pacemakers being reset during each cardiac cycle. However, in some pathologic circumstances, the rate of lower pacemakers can exceed that of the SA node, and then the lower pacemakers determine overall heart rate.⁴

An action potential, once initiated in a cardiac cell, will propagate along the cell membrane until the entire cell is depolarized. Myocardial cells have the unique property of transmitting action potentials from one cell to adjacent cells by means of direct current spread (without electrochemical synapses). In fact, until about 1954 there was almost general agreement that the myocardium was an actual syncytium without separate cell boundaries. But the electron microscope identified definite cell membranes, showing that adjacent cells separate. They are tightly coupled, however, to transmit both tension and electric current from cell to cell. The low-resistance connections are known as gap junctions. Ionic currents flow from cell to cell via these intercellular connections, and the heart behaves electrically as a functional syncytium. Thus, an impulse originating anywhere in the myocardium will propagate throughout the heart, resulting in a coordinated mechanical contraction. An artificial cardiac pacemaker, for example, introduces depolarizing electrical impulses via an electrode catheter usually placed within the right ventricle. Pacemaker-induced action potentials excite the entire ventricular myocardium resulting in effective mechanical contractions.

3. This is true for normal operating conditions. In pathological conditions, any myocardial cell may act as a pacemaker.
4. Pacemakers other than the SA node may also take over the regulation of the heart rate when faster pacemakers are not effective, such as during episodes of *AV block*; see Section 1.3.3.

However, key structures intended to modify propagation of the action potential are interspersed throughout the heart. First, there are bands of specialized conducting fibers across which the action potential travels more rapidly compared to the conduction through the myocardium. It is by traveling across a combination of conducting fibers and myocardium that the action potential can propagate to all regions of the ventricles in less than 100 milliseconds. In subjects with conduction system disease, the propagation time is prolonged because the action potential only spreads through the myocardium itself. This unsynchronized squeezing motion of various parts of the heart can cause a mild impairment of pumping efficacy. In addition to specialized conducting fibers, there are tissues that electrically insulate the ventricles from the atria. In a normal heart, the only way the action potential passes from the atria to the ventricles is through another specialized structure called the AV node, whose function is to provide a delay in conduction, so that the atria can contract completely before the ventricles begin contracting. The function and structure of the normal heart are discussed in more detail below.

It should be noted that, through decades of investigation, much detail is available about the electrophysiologic activity of the heart and the preceding text is therefore only a highly abbreviated summary. Interested readers are referred to more detailed texts such as [2, 3].

1.2 The Physical Basis of Electrocardiography

As a result of the electrical activity of the cells, current flows within the body and potential differences are established on the surface of the skin, which can be measured using suitable equipment (see Chapter 2). The graphical recording of these body surface potentials as a function of time produces the electrocardiogram. The simplest mathematical model for relating the cardiac generator to the body surface potentials is the single *dipole model*. This simple model is extremely useful in providing a framework for the study of clinical electrocardiography and vectorcardiography, though of course much more complex treatments have been developed.⁵ The descriptions in this chapter are therefore simplifications to aid the understanding of the surface potential signal that manifests as an ECG.

The dipole model has two components, a representation of the electrical activity of the heart (the dipole itself), and the geometry and electrical properties of the surrounding body. First, consider the representation of the electrical activity of the heart: as an action potential propagates through a cell (i.e., in the myocardium), there is an associated *intracellular* current generated in the direction of propagation, at the interface of resting and depolarizing tissue. This is the elementary electrical source of the surface ECG, referred to as the current dipole. There is also an equal *extracellular* current flowing against the direction of propagation, and so charge is conserved. All current loops in the conductive media close upon themselves, forming a dipole field (see Figure 1.2). The heart's total electrical activity at any instant of

5. Models include multiple dipole models, cable models and statistical models. Further information can also be found in [3–5] and Chapter 4.

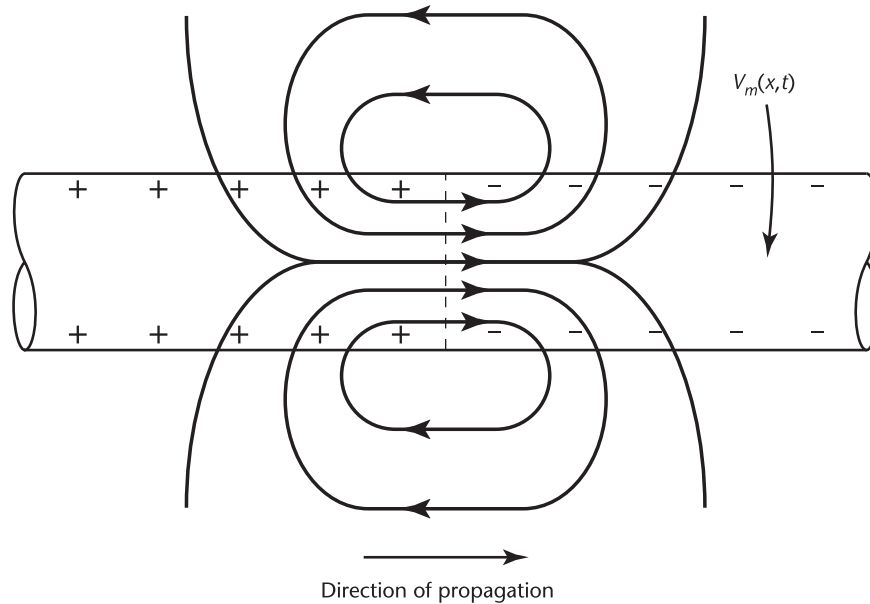


Figure 1.2 The dipole field due to current flow in a myocardial cell at the advancing front of depolarization. V_m is the transmembrane potential. (From: [2]. © 2004 MIT OCW. Reprinted with permission.)

time may be represented by a distribution of active current dipoles. In general, they will lie on an irregular surface corresponding to the boundary between depolarized and polarized tissue.

If the heart were suspended in a homogeneous isotropic conducting medium and were observed from a distance sufficiently large compared to its size, then all of these individual current dipoles may be assumed to originate at a single point in space and the total electrical activity of the heart may be represented as a *single* equivalent dipole whose magnitude and direction is the vector summation of all the minute dipoles. The net equivalent dipole moment is commonly referred to as the (time-dependent) *heart vector* $\mathbf{M}(t)$. As each wave of depolarization spreads through the heart, the heart vector changes in magnitude and direction as a function of time.

The resulting surface distribution of currents and potentials depends on the electrical properties of the torso. As a reasonable approximation, the dipole model ignores the known anisotropy and inhomogeneity of the torso and treats the body as a linear, isotropic, homogeneous, spherical conductor of radius, R , and conductivity, σ . The source is represented as a slowly time-varying single current dipole located at the center of the sphere. The static electric field, current density, and electric potential everywhere within the torso (and on its surface) are nondynamically related to the heart vector at any given time (i.e., the model is quasi-static). The reactive terms due to the tissue impedance can be neglected. Laplace's equation (which holds within the idealized homogenous isotropic conducting spherical torso) may then be solved to give the potential distribution on the torso as

$$\Phi(t) = \cos\theta(t) \frac{3|\mathbf{M}(t)|}{4\pi\sigma R^2} \quad (1.1)$$

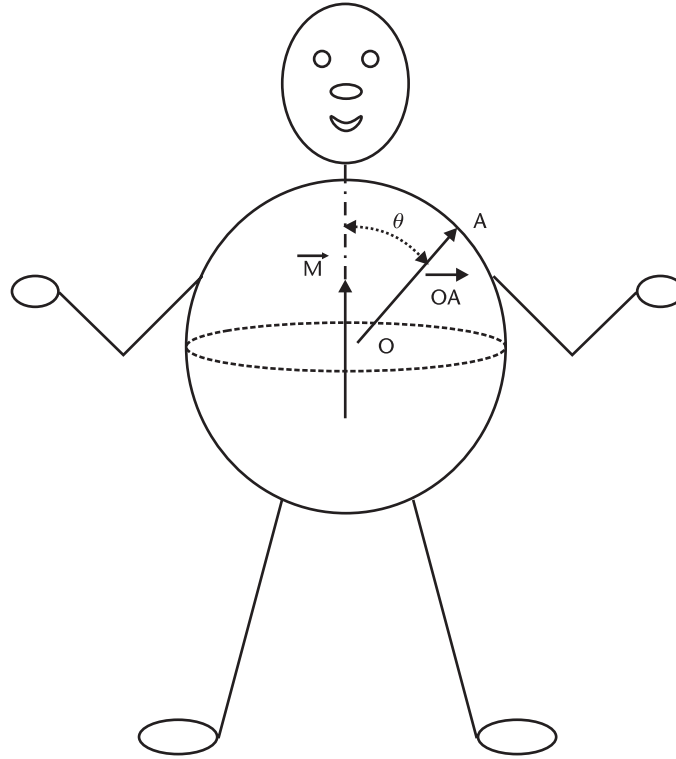


Figure 1.3 The idealized spherical torso with the centrally located cardiac source. (From: [2]. © 2004 MIT OCW. Reprinted with permission.)

where $\theta(t)$ is the angle between the direction of the heart vector $\mathbf{M}(t)$, and \mathbf{OA} the lead vector joining the center of the sphere, O , to the point of observation, A (see Figure 1.3). $|\mathbf{M}|$ is therefore the magnitude of the heart vector. More generally, the potential difference between the two points on the surface of the torso would be

$$V_{AB}(t) = \mathbf{M}(t) \cdot \mathbf{L}_{AB}(t) \quad (1.2)$$

where \mathbf{L}_{AB} is known as the lead vector connecting points A and B on the torso. It is useful to define a reference central terminal (CT) by averaging the potentials from the three limb leads (see Section 1.2.1):

$$\Phi_{CT}(t) = \Phi_{RA}(t) + \Phi_{LA}(t) + \Phi_{LL}(t) \quad (1.3)$$

where RA indicates right arm, LA indicates left arm, and LL indicates left leg. Note that Φ_{CT} should be zero at all times. The next section describes the clinical derivation of the normal ECG.

1.2.1 The Normal Electrocardiogram

The performance of the heart as a pump is dependent primarily upon the contraction and relaxation properties of the myocardium. Other factors that must also be considered include: the geometric organization of the myocardial cells, the properties of

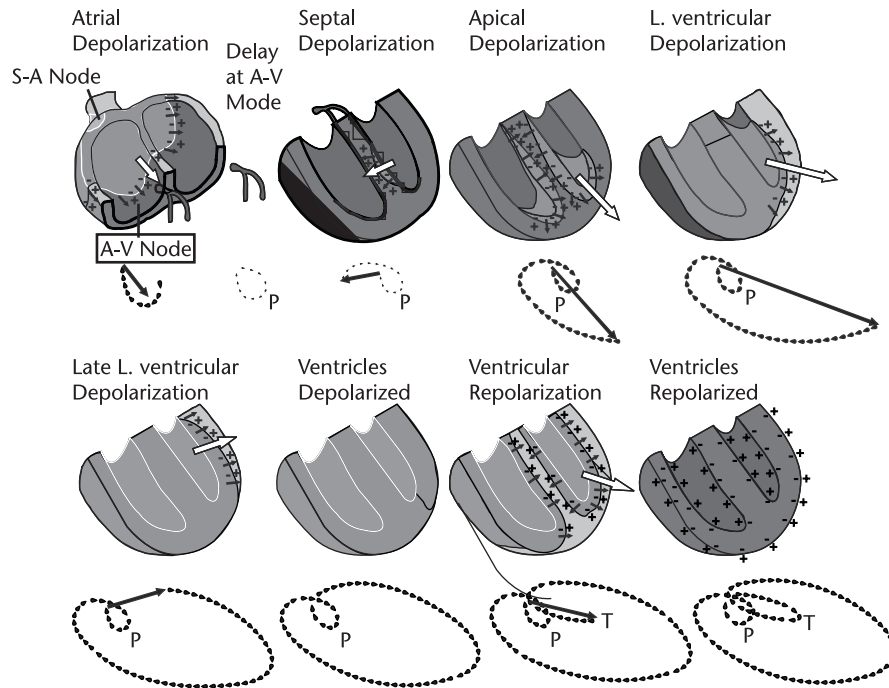


Figure 1.4 Trajectory of a normal cardiac vector. (From: [2]. © 2004 MIT OCW. Reprinted with permission.)

the cardiac tissue, the heart's electrical rhythm, valvular function, and the adequacy of delivery of oxygenated blood via the coronary arteries to meet the metabolic demands of the myocardium. The heart has four cavitory chambers whose walls consist of a mechanical syncytium of myocardial cells. At the exit of each chamber is a valve that closes after its contraction, preventing significant retrograde flow when the chamber relaxes and downstream pressures exceed chamber pressures. The *right heart* includes a small atrium leading into a larger right ventricle.⁶ The right atrium receives blood from most of the body and feeds it into the right ventricle. When the right ventricle contracts, it propels blood to the lungs, where the blood is oxygenated and relieved of carbon dioxide.⁷ The left atrium receives blood from the lungs and conducts it into the left ventricle.⁸ The forceful contractions of the left ventricle propel the blood through the aorta to the rest of the body, with sufficient pressure to perfuse the brains of even the tallest humans.⁹ The left atrium and left ventricle form the *left heart*. As noted earlier, under normal conditions the atria finish contracting before the ventricles begin contracting.

Figure 1.4 illustrates the normal heart's geometry and resultant instantaneous electrical heart vectors throughout the cardiac cycle. The figure shows the origination of the heart beat (at the SA node), a delay at the AV node (so that the

6. With a valve known as the *tricuspid* valve.
7. Its valve is the *pulmonic* valve.
8. Its valve is the *mitral* valve.
9. Its valve is the *aortic* valve.

atria, teleologically, finish contraction before the ventricles begin), and accelerated conduction of the depolarization wave via specialized conducting fibers (so that disparate parts of the heart are depolarized in a more synchronized fashion). Nine different temporal states are shown. The dotted line below each illustrated state summarizes the preceding trajectory of heart vectors. First, *atrial depolarization* is illustrated. As the wave of depolarization descends throughout both atria, the summation vector is largely pointing down (to the subject's toes), to the subject's left, and slightly anterior. Next there is the *delay at the AV node*, discussed above, during which time there is no measurable electrical activity at the body surface unless special averaging techniques are used. After activity emerges from the AV node it depolarizes the His¹⁰ bundle, followed by the bundle branches. Next, there is the *septal depolarization*. The septum is the wall between the ventricles, and a major bundle of conducting fibers runs along the left side of the septum. As the action potential wave enters the septal myocardium it tends to propagate left to right, and so the resultant heart vector points to the subject's right. Next there is apical depolarization, and the wave of depolarization moving left is balanced by the wave moving right. The resultant vector points towards the apex of the heart, which is largely pointing down, to the subject's left, and slightly anterior. In *left ventricular depolarization* and *late left ventricular depolarization*, there is also electrical activity in the right ventricle, but since the left ventricle is much more massive its activity dominates. After the various portions of myocardium depolarize, they contract via the process of excitation-contraction coupling described above (not illustrated). There is a plateau period during which the myocardium has depolarized (*ventricles depolarized*) where no action potential propagates, and hence there is no measurable cardiac vector. Finally, the individual cells begin to repolarize and another wave of charge passes through the heart, this time originating from the dipoles generated at the interface of *depolarized* and *repolarizing* tissue (i.e., *ventricular repolarization*). The heart then returns to its resting state (such that the ventricles are repolarized), awaiting another electrical stimulus that starts the cycle anew. Note that both the polarity and the direction of propagation of the repolarizing phase are reversed from those of depolarization. As a result, repolarization waves on the ECG are generally of the same polarity as depolarization waves.

To complete the review of the basis of the surface ECG, a description of how the trajectory of the cardiac vector (detailed in Figure 1.4) results in the pattern of a normal scalar ECG is now described. The cardiac vector, which expands, contracts, and rotates in three-dimensional space, is projected onto 12 different lines of well-defined orientation (for instance, lead I is oriented directly to the patient's left). Each lead reveals the magnitude of the cardiac vector in the direction of that lead at each instant of time. The six precordial leads report activity in the *horizontal* plane. In practice, this requires that six electrodes are placed around the torso (Figure 1.5), and the ECG represents the difference *between* each of these electrodes (V1–6) and the *central terminal* [as in (1.3)].

10. The His bundle is a collection of heart muscle cells specialized for electrical conduction that transmits electrical impulses from the AV node, between the atria and the ventricles to the Purkinje fibers, which innervate the ventricles.

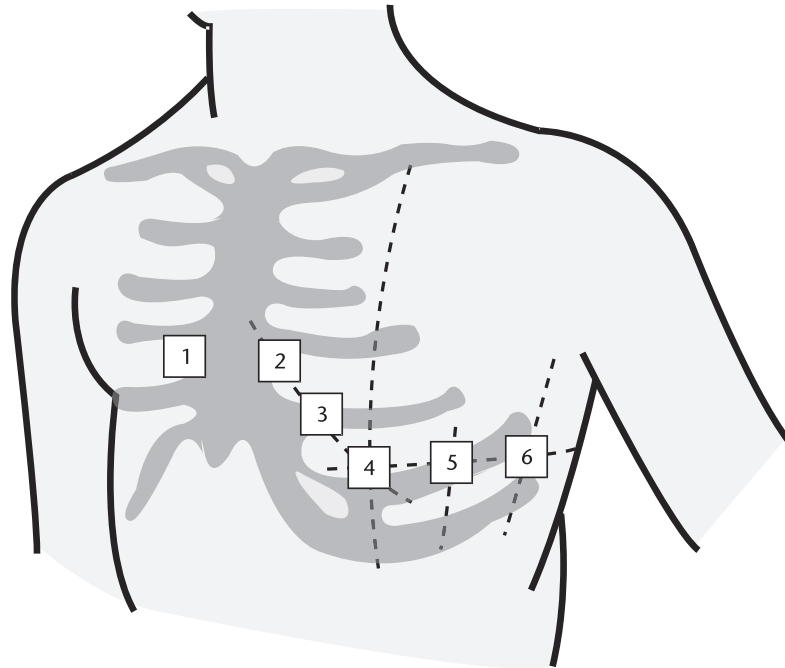


Figure 1.5 The six standard chest leads. (From: [2]. © 2004 MIT OCW. Reprinted with permission.)

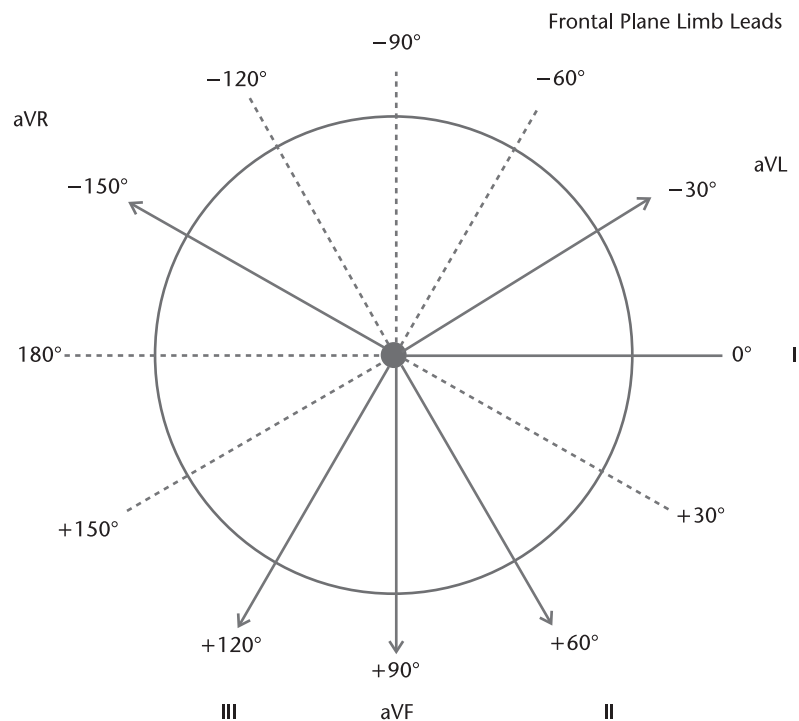


Figure 1.6 Frontal plane limb leads. (From: [2]. © 2004 MIT OCW. Reprinted with permission.)

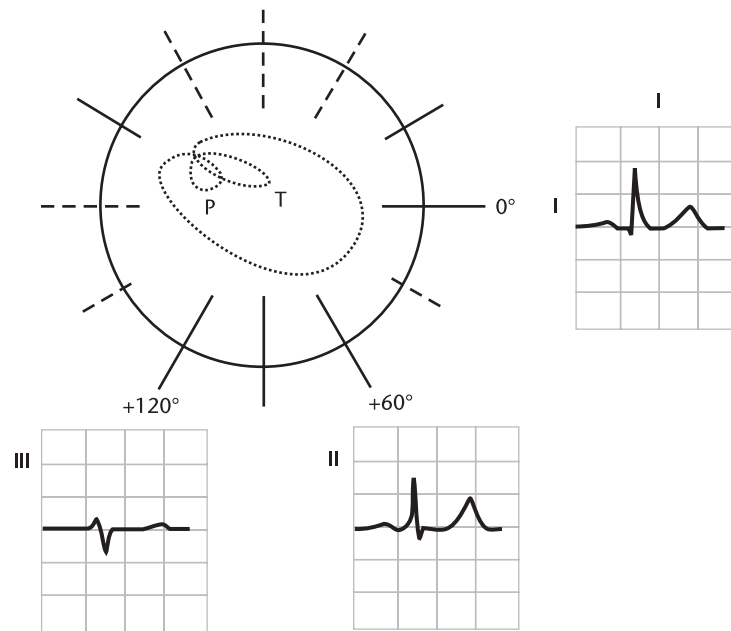


Figure 1.7 The temporal pattern of the heart vector combined with the geometry of the standard frontal plane limb leads. (From: [2]. © 2004 MIT OCW. Reprinted with permission.)

Additional electrodes, the *limb leads*, are placed on each of the subject's four extremities and the central terminal is the average of the potentials from the limb leads. Potential differences *between* the limb electrodes and the central terminal are the bases for the other three standard ECG leads, as illustrated (Figure 1.6): (1) Lead I, the difference between left arm (LA) and right arm (RA); (2) Lead II, the difference between the left leg (LL) and the RA; (3) Lead III, the difference between the LL and the LA. Note also that the augmented limb leads (denoted by "a") represent the potential at a given limb with respect to the average of the potentials of the other two limbs.¹¹ aVF is the difference between the LL and average of the arm leads; aVR is the difference between the RA and the average of LL and LA, and aVL is the difference between the LA and the average of the RA and LL. Since there are 12 leads to image three-dimensional activity, there exists considerable information redundancy in this configuration. However, this spatial "oversampling" by projecting the cardiac vector into nonorthogonal axes, tends to yield an easier representation for human interpretation and compensates for minor inconsistencies in electrode placement (after all, human forms lack geometric consistency, thus electrode placement varies with subject and with technician). Furthermore, the body is not a homogenous sphere.

The temporal pattern of the heart vector is combined with the geometry of the standard frontal plane limb leads in Figure 1.7. In black, the temporal trajectory of the heart vector, from Figure 1.4, is recreated. The frontal ECG leads are superimposed in their conventional orientation (from Figure 1.6). The resultant pattern

11. That is, the central terminal with the limb lead disconnected that corresponds to the augmented lead you are measuring. The vector is therefore longer and the signal amplitude consequently higher, hence, *augmented*.

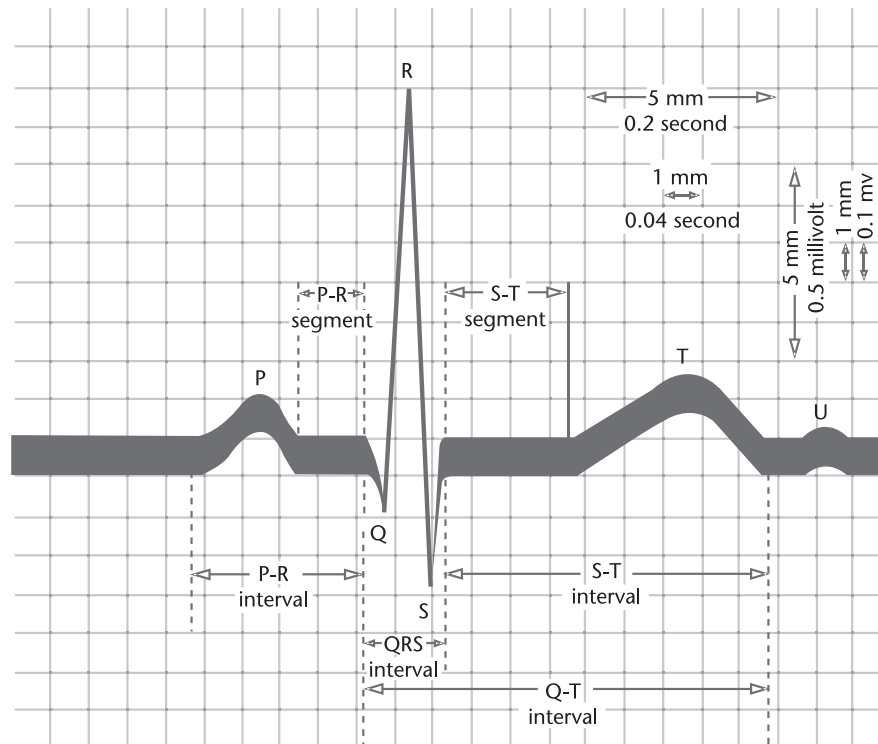


Figure 1.8 Normal features of the electrocardiogram. (From: [2]. © 2004 MIT OCW. Reprinted with permission.)

for three surface ECG leads, I, II, and III, are shown. Note that the QRS axis is perpendicular to the isoelectric lead (the lead with equal forces in the positive and negative direction). Significant changes in the QRS axis can be indicative of cardiac problems.

Figure 1.8 illustrates the normal clinical features of the electrocardiogram, which include wave amplitudes and interwave timings. The locations of different waves on the ECG are arbitrarily marked by the letters P, Q, R, S, and T¹² (and sometimes U, although this wave is often hard to identify, as it may be absent, have a low amplitude, or be masked by a subsequent beat). The interbeat timing (RR interval) is not marked. Note that the illustration uses the typical graph-paper presentation format, which stems from the early clinical years of electrocardiography, where analysis was done by hand measurements of hard copies. Each box is 1 mm² and the ECG paper is usually set to move at 25 mm/s. Therefore, each box represents 0.04 second in time. The amplitude scale is set to be 0.1 mV per square, although there is often a larger grid overlaid at every five squares (0.20 second/

12. Einthoven, who received the Nobel Prize in 1924 for his development of the first ECG, named the prominent ECG waves alphabetically, P, Q, R, S, and T. The prominent deflections were first labeled A, B, C, and D, in his preceding work with a capillary electrometer, which did not record negative deflections. The new nomenclature was to distinguish the superior signal produced by a string galvanometer. For more information, see [6].

0.5 mV).¹³ The values for the clinical features indicated on the graph in Figure 1.8 are typical, although they can vary based upon gender, age, activity, and health (see Chapter 3 and [7]).

1.3 Introduction to Clinical Electrocardiography: Abnormal Patterns

The clinician who uses the electrocardiogram as a diagnostic test wishes to determine cardiac abnormalities from the body surface potentials. As a rough framework, it is worth thinking of the heart as three separate systems: a functional electrical system, a functional system of *coronary* (or cardiac) arteries to channel nourishing blood to every cell of the myocardium, and a culmination in an effective mechanical pump.

First we consider how an ECG is used to assess electrical abnormalities of the heart. The surface ECG has inherent limitations as a diagnostic tool: Given a distribution of body surface potentials, we cannot precisely specify the detailed electrophysiologic behavior of the source since this *inverse* problem does not have a unique solution (as demonstrated in 1853 by Hermann von Helmholtz). It is not, in general, possible to uniquely specify the characteristics of a current generator from the external potential measurements alone. Therefore, an exacting assessment of the electrical activity of the heart involves an invasive electrode study. Despite these inherent limitations, the surface ECG is extremely useful in clinical assessments of electrical pathologies and an invasive electrophysiologic study is indicated in only a small fraction of cases.

To a first approximation, electrical problems come in two forms: those which make the heart pump too slowly or infrequently (bradycardias), and those which make the heart pump too quickly (tachycardias). If the pumping is too slow, the cardiac output of life-sustaining blood can be dangerously low. If too quick, the cardiac output can also be too low since the heart does not have time to fill, and also because the heart can suffer damage (e.g., *demand ischemia*) when it tries to pump too rapidly.

1.3.1 The Normal Determinants of Heart Rate: The Autonomic Nervous System

One class of heart rate abnormalities arises from abnormal function of the control system for heart rate. As discussed in Section 1.2.2, there are specialized cells in the SA node whose function is to act as the heart's pacemaker, rhythmically generating action potentials and triggering depolarization for the rest of the heart (recall that once any portion of the heart depolarizes, the wavefront tends to propagate throughout the entire myocardium). The SA node has an intrinsic rate of firing, but ordinarily this is modified by the *central nervous system*, specifically, the *autonomic nervous system* (ANS).¹⁴ The decision-making for autonomic functions occurs in

13. In this chapter, this larger amplitude scale was used for Figures 1.9 through 1.23 and Figure 1.26.

14. The part of the nervous system that functions without conscious thought, taking care of such tasks as breathing while you sleep, thermoregulation, and optimizing heart rate.

the medulla in the brain stem and the hypothalamus. Instructions from these centers are communicated via nerves that connect the brain to the heart. There are two main sets of nerves serving the *sympathetic* and the *parasympathetic* portions of the autonomic nervous system, which both *innervate* the heart. The sympathetic nervous system is activated during stressful times. It increases the rate of SA node firing (hence raising heart rate) and also innervates the myocardium itself, increasing the propagation speed of the depolarization wavefront, mainly through the AV node, and increasing the strength of mechanical contractions. These effects are all consequences of changes to ion channels and gates that occur when the cells are exposed to the messenger chemical from the nerves. The time necessary for the sympathetic nervous system to actuate these effects is on the order of 15 seconds.

The sympathetic system works in tandem with the parasympathetic system. For the body as a whole, the parasympathetic system controls quiet-time functions like food digestion. The nerve through which the parasympathetic system communicates with the heart is named the *vagus*.¹⁵ The parasympathetic branch's major effect is on heart rate and the velocity of propagation of the action potential through the AV node.¹⁶ Furthermore, in contrast with the sympathetic system, the parasympathetic nerves act quickly, decreasing the velocity through the AV node and slowing the heart rate within a second when they activate. Most organs are innervated by both the sympathetic and the parasympathetic branches of the ANS and the balance between these competing effects determines function.

The sympathetic and parasympathetic systems are rarely totally off or on; instead, the body adjusts their levels of activation, known as *tone*, as is appropriate to its needs. If a medication that inactivates the sympathetic system (e.g., propranolol) is used on a healthy resting subject with a heart rate of 60 bpm, the classic response is to slow the heart rate to about 50 bpm. If a medication that inactivates the parasympathetic system (e.g., atropine) is used, the classic response is an elevation of the heart rate to about 120 bpm. If you administer both medications and inactivate both systems (parasympathetic and sympathetic withdrawal), the heart rate rises to 100 bpm. Therefore, in this instance for normal subjects at rest, the effects of the heart rate's "brake" are greater than the effects of the "accelerator," although it is the balance of both systems that dictates the heart rate. The body's normal reaction when vagal tone is increased (the brake) is to simultaneously reduce sympathetic tone (the accelerator). Similarly, when sympathetic tone is increased, parasympathetic tone is usually withdrawn. Indeed, if a person is suddenly startled, the earliest increase in heart rate will simply be due to parasympathetic withdrawal rather than the slower-acting sympathetic activation.

On what basis does the autonomic system make heart rate adjustments? There are a series of sensors throughout the body sending information back to the brain (*afferent nerves*, bringing information to the central nervous system). Those parameters sensed by afferent nerves include the blood pressure in the arteries (baroreceptors), the acid-base conditions in the blood (chemoreceptors), and the pressure within the heart's walls (mechanoreceptors). Based on this feedback, the brain unconsciously adjusts heart rate. The system is predicated on the fact that,

15. Parasympathetic activity is therefore sometimes termed *vagal* activity.

16. It has little effect on cardiac contractility.

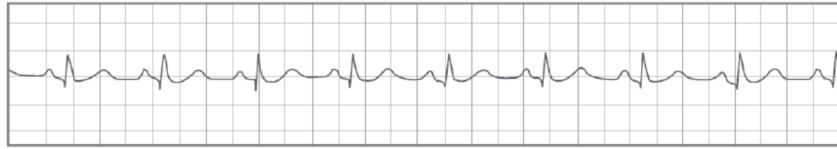


Figure 1.9 Normal sinus rhythm. (From: [2]. © 2004 MIT OCW. Reprinted with permission.)

as heart rate increases, cardiac pumping and blood output should increase, and so increase arterial blood pressure, blood flow and oxygen delivery to the peripheral tissues, carbon dioxide clearance from the peripheral tissues, and so on.

When the heart rate is controlled by the SA node's rate of firing, the sequence of beats is known as a *sinus rhythm* (see Figure 1.9). When the SA node fires more quickly than usual (for instance, as a normal physiologic response to fear, or an abnormal response due to a cocaine intoxication), the rhythm is termed *sinus tachycardia* (see Figure 1.10). When the SA node fires more slowly than usual (for instance, either as a normal physiologic response in a very well-conditioned athlete, or an abnormal response in an older patient taking too much heart-slowing medication), the rhythm is known as *sinus bradycardia* (see Figure 1.11). There may be cyclic variations in heart rate due to breathing, known as *sinus arrhythmia* (see Figure 1.12). This nonpathologic pattern is caused by activity of the parasympathetic system (the sympathetic system responds too slowly to alter heart rate on this time scale), which is responding to subtle changes in arterial blood pressure, cardiac filling pressure, and the lungs themselves, during the respiratory cycle.

Sinus Tachycardia—Rate 122

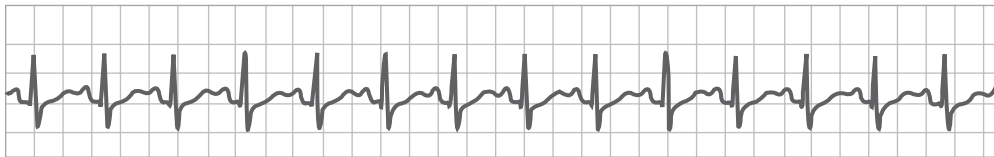


Figure 1.10 Sinus tachycardia. (From: [2]. © 2004 MIT OCW. Reprinted with permission.)

Sinus Bradycardia—Rate 48

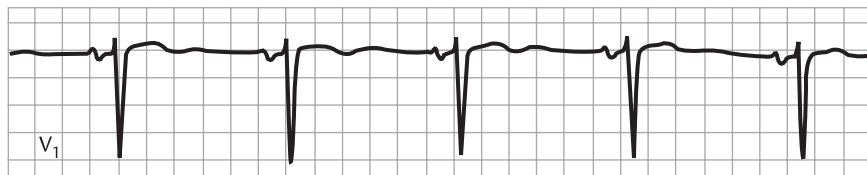

Figure 1.11 Sinus bradycardia. (From: [2]. © 2004 MIT OCW. Reprinted with permission.)

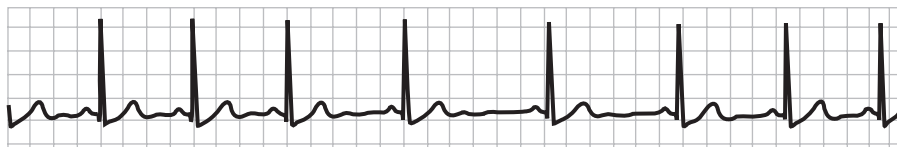


Figure 1.12 Sinus arrhythmia. (From: [2]. © 2004 MIT OCW. Reprinted with permission.)

1.3.2 Ectopy, Tachycardia, and Fibrillation

An *arrhythmia* is any abnormal cardiac rhythm. One category of arrhythmias occurs when the trigger to depolarize originates outside of the SA node, in another part of the myocardium (known as *ectopic depolarization*, leading to *ectopic beats*). Common causes of ectopy include a drug effect (e.g., caffeine) or a viral infection of the myocardium, or other inflammation or damage of part of the heart (e.g., ischemia). When the ectopic beat originates in the atria, it leads to a *premature atrial beat*, also known as an *atrial premature contraction (APC)* (see Figure 1.13). When it originates in the ventricles, it leads to a *premature ventricular beat* or *ventricular premature contraction (VPC)*; see Figure 1.14.

Note in Figure 1.14 that the ectopic ventricular beat looks very different from the other sinus beats. The spread of the wavefront for a VPC can be backwards, such as when the action potential starts at the apex of the heart rather than the septum. The depolarization wavefront can move in very different directions than the typical sinus-driven heart vector. Compare Figure 1.15 with the wavefront trajectory in

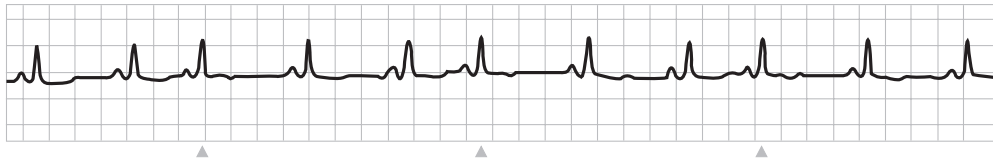


Figure 1.13 Atrial premature contractions (indicated by arrowheads). (From: [2]. © 2004 MIT OCW. Reprinted with permission.)

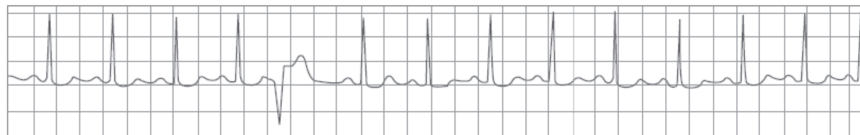


Figure 1.14 Ventricular premature contractions. (From: [2]. © 2004 MIT OCW. Reprinted with permission.)

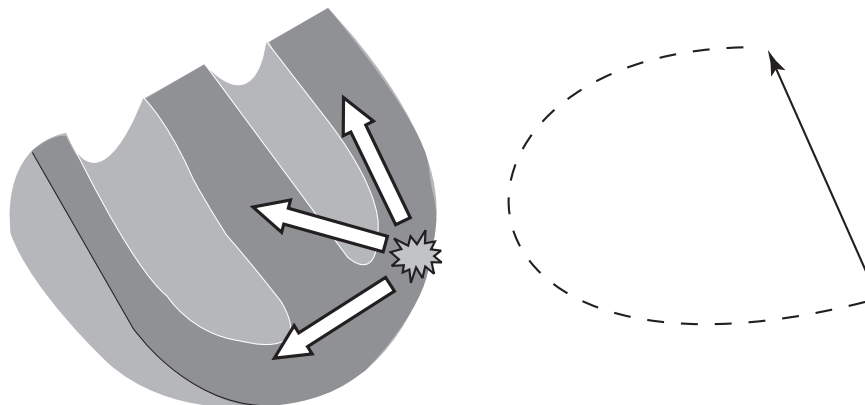


Figure 1.15 Wavefront trajectory in a ventricular premature contraction. (From: [2]. © 2004 MIT OCW. Reprinted with permission.)

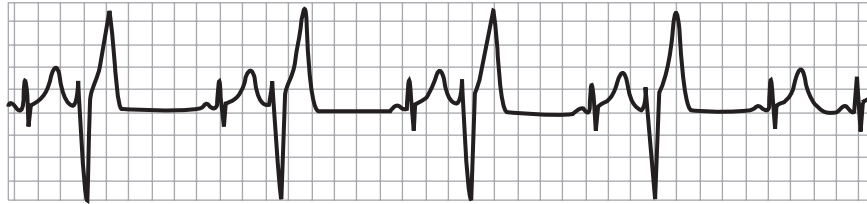


Figure 1.16 Ventricular bigeminy. (From: [2]. © 2004 MIT OCW. Reprinted with permission.)

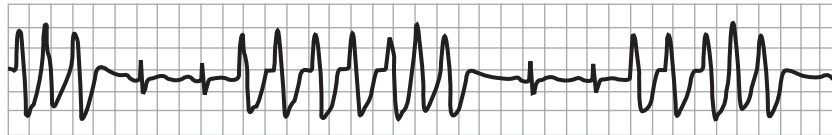


Figure 1.17 Three episodes of nonsustained ventricular tachycardia. There are two normal sinus beats in between each episode of VT. (From: [2]. © 2004 MIT OCW. Reprinted with permission.)

Figure 1.4. Furthermore, the ectopic beat is typically wider because its wavefront propagates slowly through the myocardium rather than through the high-speed Purkinji system.

After an ectopic wavefront has propagated to all portions of the heart, the myocardium is left temporarily depolarized. After a pause, the tissue repolarizes and the regular sinus mechanism can instigate a subsequent beat. The conditions that caused the ectopic beat might persist (e.g., still too much caffeine leading to an excitable myocardium), but the ectopic beat itself is left behind in the past. Sometimes, a semistable pattern of sinus beats and ectopic beats develops. For instance, a repeating pattern of “sinus beat – VPC – sinus beat – VPC – and so forth.” can occur, termed *ventricular bigeminy* (see Figure 1.16). There can be so many ectopic beats ongoing that the overall heart rate is driven much higher than normal.¹⁷

The potential for serious problems is higher for those less common conditions in which a wavefront continues to propagate in a quasi-stable state, circulating repeatedly through the heart leading to repeated waves of tissue depolarization at an abnormally high rate.¹⁸ When this cyclic, quasi-stable phenomenon occurs in the heart, it is called a *reentrant* arrhythmia. A classic example often caused by a reentrant pattern is *ventricular tachycardia* (VT) (see Figure 1.17). These states are extremely pathologic and can be rapidly fatal, because the rate of depolarization can be incompatible with effective cardiac pumping. At one extreme (rapid VT in an older frail heart) VT can be fatal in seconds to minutes. At the other extreme

17. For instance, *multifocal atrial tachycardia* (MAT) is an arrhythmia in which two or more ectopic atrial sites generate ectopic beats leading to heart rates greater than 100 bpm. The classic MAT finding on ECG is three or more P wave morphologies, due to the normal sinus beats plus two or more atrial ectopic foci.
18. To understand this, it is useful to describe the process in terms of “excitable media” models [4, 5]. Consider the analogy of the wavefront acting like a wildfire propagating through a landscape. If the vegetation grew back quickly (in a matter of minutes), one could envision a state in which the fire rotated through the forest in a large circle in a sustained fashion, and continued to “burn” vegetation just as it grew back. It might also be intuitive that this state would be more stable if there was a large fire barrier at the center of this rotation.

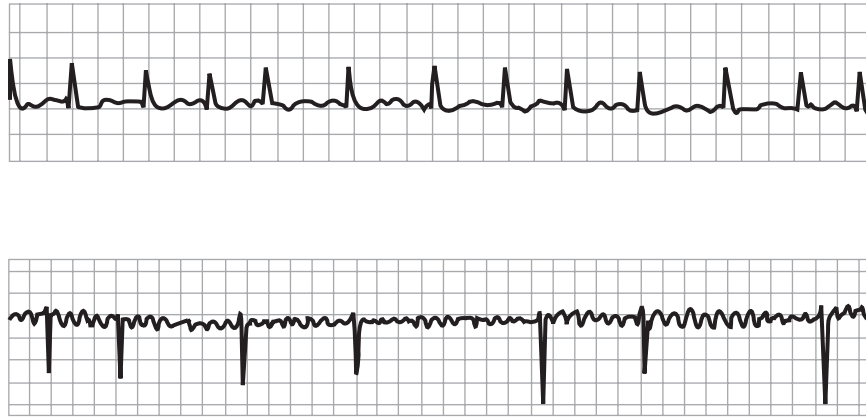

Figure 1.18 Atrial fibrillation—two examples. (From: [2]. © 2004 MIT OCW. Reprinted with permission.)

(slow VT in a younger healthy heart) the cardiac output¹⁹ can remain at a life-sustaining level. The ECG criteria for VT are three or more consecutive ectopic ventricular beats at a rate over 100 bpm. If the VT terminates within 15 seconds (or 30 seconds, by some conventions) it is known as *nonsustained VT*; otherwise it is *sustained VT*. Because of the grave medical consequences of VT and related reentrant arrhythmias, they have been well investigated experimentally, clinically, and theoretically.

In some cases, the unified wavefront of depolarization can break down into countless smaller wavefronts which circulate quasi-randomly over the myocardium. This leads to a total breakdown of coordinated contraction, and the myocardium will appear to quiver. This is termed *fibrillation*. In *atrial fibrillation* (see Figure 1.18) the AV node will still act as a gatekeeper for these disorganized atrial wavefronts, maintaining organized ventricular depolarization distal to the AV node with normal QRS complexes. The ventricular rhythm is generally quite irregular and the rate will often be elevated. Often atrial fibrillation is well tolerated, provided the consequent ventricular rate is not excessive. AF can lead to a minor impairment in cardiac output due to reduced ventricular filling. In the long term, there can be regions in a fibrillating atrium where, because of the absence of contractions, the blood sits in stasis, and this can lead to blood clot formation within the heart. These clots can reenter the circulation and cause acute arterial blockages (e.g., cerebrovascular strokes) and therefore patients with atrial fibrillation are often anticoagulated. In contrast to atrial fibrillation, untreated *ventricular fibrillation* (see Figure 1.19) is fatal in seconds to minutes: The appearance of fibrillating ventricles has been likened to a “bag of worms” and this causes *circulatory arrest*, the termination of blood flow through the cardiovascular circuit.

19. The volume of blood pumped by the heart per minute, calculated as the product of the stroke volume (SV) and the heart rate. The SV is the amount of blood pushed into the aorta with each heart beat. Stroke volume = end-diastolic volume (EDV) minus end-systolic volume (ESV).

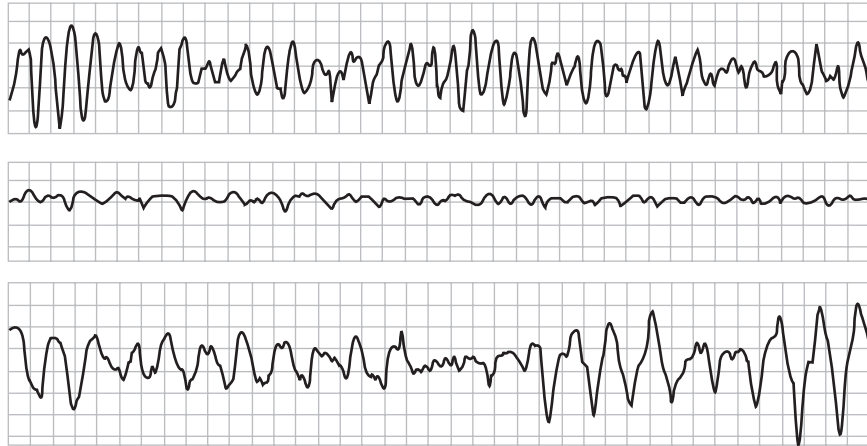


Figure 1.19 Ventricular fibrillation—three examples. (From: [2]. © 2004 MIT OCW. Reprinted with permission.)

1.3.3 Conduction Blocks, Bradycardia, and Escape Rhythms

The other category of arrhythmias is related to excessively slow rhythms, and abnormal blockages of wavefront propagation. For instance, an aging SA node may pace the heart too slowly, leading to low blood pressure and weakness or fainting. Assuming this is not a result of excessive medication, these symptoms might require that an artificial pacemaker be implanted. The AV node may also develop conduction pathologies which slow the ventricular heart rate: It may fail to conduct *some* atrial wavefronts (termed *second-degree AV block*; see Figure 1.20), or it may fail to conduct *all* atrial wavefronts (termed *third-degree AV block*; see Figure 1.21). Assuming this is not a result of excessive medication, most third-degree AV block, and some second-degree AV block, require pacemaker therapy. In first-degree AV block, the AV node conducts atrial wavefronts with an abnormal delay, but because the atrial wavefronts are eventually propagated to the ventricles, first-degree AV block does not slow the overall ventricular rate.

Sections of the specialized conducting fibers in the ventricles can also fail, such that depolarization waves must reach some portions of the ventricles via slower

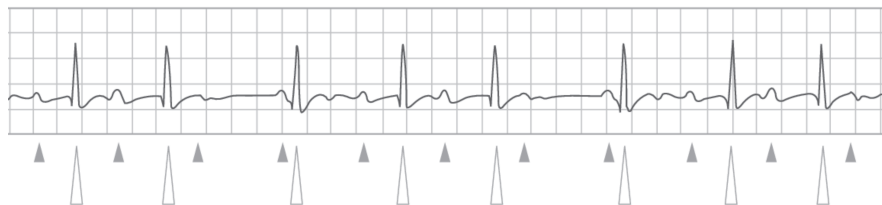


Figure 1.20 Second-degree AV block. In this subtype of second-degree AV block, termed *Wenckebach*, also termed *Mobitz Type I*, there is a characteristic lengthening of the delay between the atrial P wave and the ventricular QRS, and ultimately there is a failure to conduct a P wave. Then this cycle repeats. In the example illustrated, there are three P waves (indicated by small gray arrowheads) followed by ventricular beats (indicated by large white arrowheads), and then the AV node fails to conduct the fourth P wave in each cycle (small gray arrowheads without a subsequent large white arrowheads). (From: [2]. © 2004 MIT OCW. Reprinted with permission.)

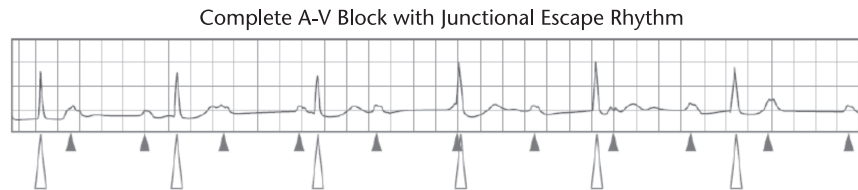


Figure 1.21 Third-degree AV block. There is a failure of the AV node to conduct any wavefronts from the atria to the ventricles. The ventricular beats are escape beats, originating electrically from the specialized conducting fibers just below the AV node. The ability to generate escape beats is the heart's fail-safe mechanism for what would otherwise cause fatal cardiac (e.g., ventricular) arrest. Notice there is no relationship between the atrial P waves (indicated by small gray arrowheads) and the junctional escape beats (indicated by large white arrowheads). Also see Figure 1.23 for an example of a ventricular escape beat. (From: [2]. © 2004 MIT OCW. Reprinted with permission.)

muscle-to-muscle propagation. There are a classic set of changes associated with failures of different conduction bundles (e.g., *right bundle branch block* and *left bundle branch block*; see Figure 1.22). These blocks usually have a minimal effect on pumping efficacy. However, they can dramatically change the cardiac vector's trajectory and hence the surface ECG. They can mask other ECG changes indicative of disease (e.g., ischemia). In some cases, these conduction abnormalities indicate some other underlying pathology of great importance (for instance, a pulmonary embolism can cause a new right bundle branch block, and acute anterior ischemia can cause a new left bundle branch block).

The topic of bradyarrhythmias and heart blocks leads to the topic of *escape beats* (see Figures 1.21 and 1.23). An escape beat is similar to an ectopic beat, in that it is the initiation of a depolarization wavefront outside of the SA node. However, the difference is that the escape beat is a normal, compensatory response, a normal fail-safe functionality of the heart: There is a network of cardiac cells able to initiate

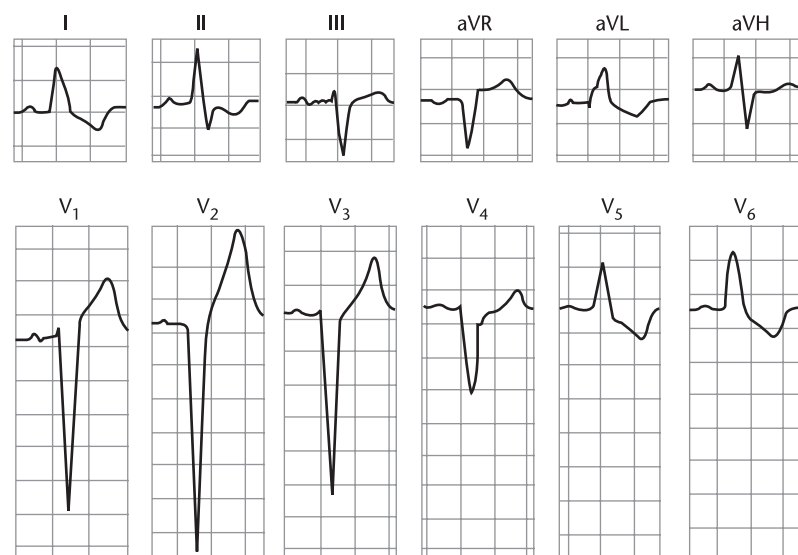


Figure 1.22 Classic ECG pattern of left bundle branch block. (From: [2]. © 2004 MIT OCW. Reprinted with permission.)

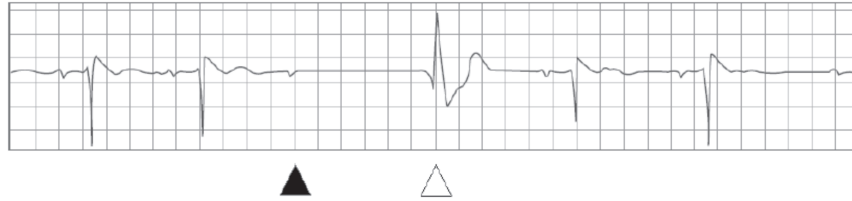


Figure 1.23 Ventricular escape beat. Note the atrial P wave (black arrowhead) followed by an evident pause, indicating a failure to conduct through the AV node. The ventricular escape beat (white arrowhead) is a fail-safe mechanism so that conduction blocks do not cause ventricular cardiac arrest. Also see Figure 1.21. (From: [2]. © 2004 MIT OCW. Reprinted with permission.)

heart beats, so that a key life-sustaining function (e.g., pacing the heart) is not exclusively relegated to a microscopic collection cells in the SA node. The cells in the backup system have intrinsic rates of firing that are slower than the SA node. So while the SA node is given the opportunity to pace the heart, the other regions will initiate heart beats if there has been an excessively long pause in the SA node. Therefore, a ventricular beat which occurs in the setting of third-degree heart block is termed a ventricular escape beat, and it represents an appropriate healthy response to the lack of any other pacemaker trigger. When nonsinus beats appear on the ECG, it is important to differentiate ectopic beats (where the pathology is aberrant automaticity) from escape beats (where the pathology is abnormal conduction), because the treatments are quite different. Note that ectopic beats are generally premature, and escape beats terminate a prolonged RR interval.

1.3.4 Cardiac Ischemia, Other Metabolic Disturbances, and Structural Abnormalities

The ECG can reveal metabolic abnormalities of the myocardium. The most medically significant abnormality is *ischemia*, when part of the myocardium is not receiving enough blood flow, often caused by disease of the coronary arteries (ischemia will ultimately progress to myocardial cell death). Recording a 12-lead ECG is a standard-of-care diagnostic test in any evaluation of possible cardiac ischemia. Ischemia often changes the appearance of the T wave and the ST interval. This is because of a current of injury between the ischemic and nonischemic myocardium, which alters the main cardiac vector. There are classic patterns of ischemia, which are seen in only a minority of ischemic events (see Figure 1.24). In most ischemic events, there are “nonspecific” ECG changes, such as changes in the T wave that may or may not be caused by ischemia. In a small percentage of cases, there can be ischemia without any grossly evident ECG changes. Overall, the ECG is not highly sensitive nor specific for cardiac ischemia, but larger regions of cardiac ischemia are associated with more substantial ECG changes (as well as a higher mortality rate), so this information is very useful in decision-making. For example, a patient with classic changes of acute ischemia is often a good candidate for powerful thrombolytic (clot dissolving) medication. Whereas patients without those classic changes are not considered good candidates for these drugs because, on average, the risks of the therapy, including intracranial hemorrhage and internal bleeding, outweigh the benefits.

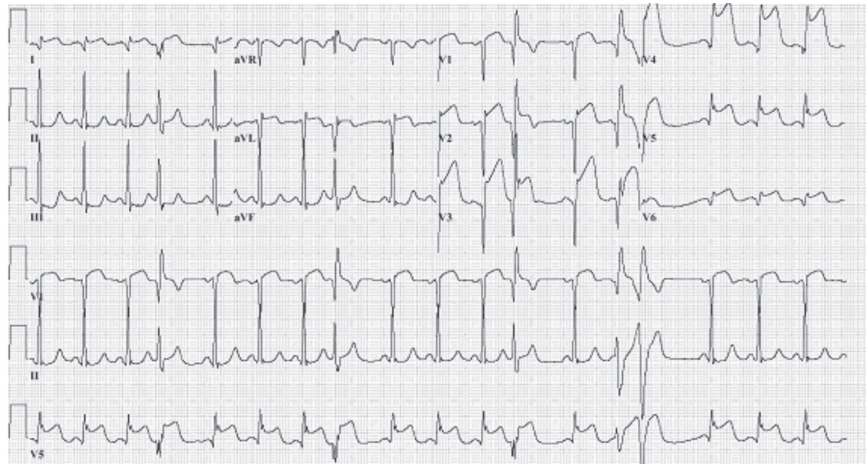


Figure 1.24 Acute myocardial infarction. Large areas of ischemic anterior myocardium often produce ST-segment elevation in multiple contiguous precordial ECG leads (or in *all* the precordial leads, in this dramatic example). Also note there is minor ST-segment depression in the inferior lead III, which in this context is referred to as a “reciprocal change.” (From: [9]. © 2001–2006 Beth Israel Deaconess Medical Center. Reprinted with permission.)

Other metabolic abnormalities which cause characteristic changes in the ECG include electrolyte abnormalities. The classic indicators of high serum potassium levels (*hyperkalemia*) include a high, pointed T wave, and ultimately, loss of the P wave and distortion of the QRS (see Figure 1.25). *Hypokalemia* causes an undulation after the T wave called a U wave. Calcium and magnesium disturbances, and

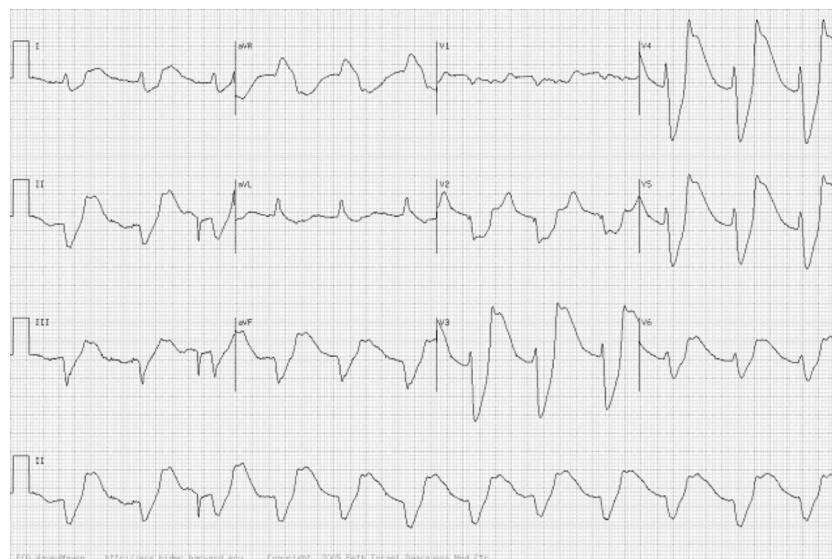

Figure 1.25 Hyperkalemia (moderate/severe). The K^+ was 10.5 mEq/L in a patient with renal failure. Note the loss of P waves and the widening of the QRS complex. There are numerous classic ECG morphologies associated with hyperkalemia. This example shows what Marriott [8] has termed a “dumping pattern” because “it looks as though a rotund body has been dumped in the hammock of the ST segment . . . making the ST segment sag horizontally . . . and verticalizing the proximal limb of the upright T wave.” (From: [9]. © 2001–2006 Beth Israel Deaconess Medical Center. Reprinted with permission.)

R-on-T VPB Initiates Ventricular Flutter




Figure 1.26 An R-on-T ventricular premature beat initiates polymorphic ventricular tachycardia. (From: [2]. © MIT OCW. Reprinted with permission.)

also extreme cold body temperature, are other causes of ST-T wave abnormalities. Therapeutic drugs can also alter the appearance of the ECG. One alteration of significance is a delay in the T wave relative to the QRS, so-called *QT prolongation*. A prolonged²⁰ QT indicates a myocardium at risk for *triggered activity*, in which a cardiac cell will rapidly and repeatedly depolarize, associated with a kind of dangerous ventricular tachycardia called *torsades des pointes*. In the so-called R-on-T phenomenon, the heart depolarizes in the midst of its repolarization and can trigger a life-threatening tachyarrhythmia (see Figure 1.26). R-on-T can occur because the QT interval is abnormally long. It also can occur because of a mechanical blow to the chest during repolarization (e.g., a young hockey player struck in the chest). And relevant to signal processors, it can occur if a patient receives electrical cardioversion in the middle of repolarization when the T wave occurs (hence these devices are imbued with a synchronization mode in which the QRS complex is automatically identified, and the device is prevented from discharging in the temporal vicinity of the following T wave).

The ECG can reveal abnormalities of the geometry of the heart. This refers to pathologies in which part of the heart has become enlarged (too much myocardium), or when part of the heart has undergone cell death and scarring (electrically absent myocardium). Noninvasive echocardiography is now the standard method by which such abnormalities are diagnosed, and so in general, the ECG has been relegated to a convenient if imperfect screening test for structural abnormalities of the heart. Examples of conditions which are often apparent in the surface ECG include:

- Thickening of the ventricular walls caused by years of beating against high arterial blood pressure (hypertrophy);
- Ballooning of the ventricular walls caused by accommodating large volumes of blood regurgitated from upstream when there is a leaky, incompetent valve;
- Ventricular wall aneurysms which form after heart attacks;
- Scars in the heart (after heart attacks) which cause part of the heart to be electrically silent;
- Abnormal fluid collecting around the heart (termed an *effusion*) which can impair the heart's ability to fill and hence pump effectively (*cardiac tamponade*).

20. It is important to allow for the shortening of the QT interval due to increases in heart rate, and so a *corrected* QT interval, QTc, is usually used. See Chapter 3 for more details.

These conditions change the trajectory and/or magnitude of the normal heart vector, which can distort the normal ECG morphology. A review of all these conditions and their resultant ECG appearance is beyond the scope of this chapter, and introductory or advanced textbooks focused solely on the clinical interpretation of the ECG are plentiful. However, in the following section a brief overview of how clinicians analyze the ECG is presented. This should not be taken as a definitive guide, but as a general strategy that may prove useful in designing an ECG analysis algorithm.

1.3.5 A Basic Approach to ECG Analysis

In analyzing the clinical electrocardiogram, it is important to use a systematic approach. The following overview, which illustrates a clinical approach, should not be considered completely thorough, but simply a guide to understanding how clinicians identify abnormalities in the ECG.

1. *Identify the QRS complexes.* The following observations should be made:
 - What is the ventricular rate?
 - Are the QRS complexes spaced at regular intervals? If not, what is the nature of the irregularity?
 - Are the QRS complexes identical in shape in a given lead? Are they of normal size and morphology?
2. *Identify the P waves.* In some cases this will require careful observation, and more than one lead axis may be necessary. The following questions should be explored:
 - Is there a one-to-one relationship between P-waves and QRS complexes? If not, is there a definable pattern?
 - Is the PR interval of normal duration?
 - What is the atrial rate?
 - Are the P waves identical in shape in a given lead? Are they of normal size and shape?

Based on the above analysis, it should be possible to identify the mechanism of the rhythm in most cases. See Chapter 3 for more information.

3. *Examine the QRS complex in each lead.* Is the QRS axis normal? Overall, are the QRS widths and amplitudes normal? Often, the QRS complexes are viewed in several “groups” that are specific to a particular region of the heart.²¹ The waveform patterns should also be checked for signs of intraventricular conduction block, significant amplitude Q waves and precordial R-wave pattern normality.
4. *Examine the ST-T segments.* Are there abnormalities (such as elevation or depression; see Chapter 10)? Is the abnormality suggestive of ischemia, infarction, or hypothermia?

21. The basic lead groups are: the *inferior* leads (II, III, and aVF), the *anterior* leads (V2, V3, and V4), the *lateral* precordial leads (V4, V5, and V6), and the *high lateral* leads (I and aVL).

5. *Examine the T waves.* Are their shapes normal? In each lead, are they oriented in the same direction as the QRS complex? If not, is it suggestive of ischemia or ventricular conduction abnormalities, or a potassium abnormality?
6. *Examine the QT interval.* Is it over half the RR interval? (See Chapters 3 and 11.)

Once an abnormality is identified, there are often several potential explanations, many of which lead to several ECG pathologies and it may not be possible to determine the significance of the abnormality with certainty. To confirm a potential diagnosis from the ECG, other characteristic abnormalities are often sought. For a given individual, comparing a new ECG with a prior ECG provides an invaluable reference, particularly if trying to ascertain when ECG abnormalities are acute or not. For instance, for a patient with chest pain, abnormal ST-T wave patterns are much more concerning for ischemia when they are new (e.g., not present in an ECG recorded 1 year earlier). If the ST-T wave patterns existed long before the new symptoms, one may deduce that these patterns are not directly related to the acute pathology.

1.4 Summary

This chapter has presented a brief summary of the etiology of the electrocardiogram, together with an overview of the mechanisms that lead to the manifestation of both normal and abnormal morphologies on the many different vectors that constitute the clinical ECG leads. After an overview of the variables to be considered in any ECG data collection exercise (Chapter 2), Chapters 3 and 4 provide a more mathematical analysis of the normal and abnormal waveforms that may be encountered, and some empirical models available for describing these waveforms (or their underlying processes). It is hoped that these introductory chapters will provide the reader with the relevant framework in which to apply numerical analysis techniques to the ECG.

References

- [1] Mark, R. G., "Biological Measurement: Electrical Characteristics of the Heart," in *Systems & Control Encyclopedia*, Singh, M. G., (ed.), Oxford, U.K.: Pergamon Press, 1990, pp. 450–456.
- [2] Mark, R. G., *HST.542J/2.792J/BE.371J/6.022J Quantitative Physiology: Organ Transport Systems*, Lecture notes from HST/MIT Open Courseware 2004, available at <http://ocw.mit.edu/OcwWeb/Health-Sciences-and-Technology/HST-542JSpring-2004/CourseHome/>.
- [3] Malmivuo, J., and R. Plonsey, *Bioelectromagnetism: Principles and Applications of Bioelectric and Biomagnetic Fields*, Oxford, U.K.: Oxford University Press, 1995, available at <http://butler.cc.tut.fi/~malmivuo/bem/bembook/>.
- [4] Barkley, D., M. Kress, and S. Turcherman, "Spiral-Wave Dynamics in a Simple Model of Excitable Media: Transition from Simple to Compound Rotation," *Phys. Rev. A.*, Vol. 42, 1990, pp. 2489–2491.

- [5] Ito, H., and L. Glass, "Spiral Breakup in a New Model of Discrete Excitable Media," *Phys. Rev. Lett.*, Vol. 66, No. 5, 1991, pp. 671–674.
- [6] Katz, A. M., *Physiology of the Heart*, 4th ed., Philadelphia, PA: Lippincott Williams & Wilkins, 2006.
- [7] Fletcher, G. F., et al., "Exercise Standards; A Statement for Healthcare Professionals from the American Heart Association," *Circulation*, Vol. 91, 2001, p. 580.
- [8] Marriott, H. J. L., *Emergency Electrocardiography*, Naples: Trinity Press, 1997.
- [9] Nathanson, L. A., et al., "ECG Wave-Maven: Self-Assessment Program for Students and Clinicians," <http://ecg.bidmc.harvard.edu>.

Selected Bibliography

- Alexander, R. W., R. C. Schlant, and V. Fuster, (eds.), *Hurst's The Heart*, 9th ed., Vol. 1, *Arteries and Veins*, New York: McGraw-Hill, Health Professions Division, 1998.
- El-Sherif, N., and P. Samet, *Cardiac Pacing and Electrophysiology*, 3rd ed., Philadelphia, PA: Harcourt Brace Jovanovich, Inc., W. B. Saunders Company, 1991.
- Gima, K., and Y. Rudy, "Ionic Current Basis of Electrocardiographic Waveforms: A Model Study," *Circulation*, Vol. 90, 2002, pp. 889–896.
- Katz, E., *Willem Einthoven; A Biography*, 2005, available at <http://chem.ch.huji.ac.il/~eugeniik/history/einthoven.html>.
- Lilly, L. S., *Pathophysiology of Heart Disease*, 3rd ed., Philadelphia, PA: Lippincott Williams & Wilkins, 2002.
- Marriott, H. J., *Rhythm Quizlets: Self Assessment*, 2nd ed., Baltimore, MD: Williams & Wilkins, 1996.
- Massie, E., and T. J. Walsh, *Clinical Vectorcardiography and Electrocardiography*, Chicago, IL: The Year Book Publishers, Inc., 1960.
- Netter, F. H., *A Compilation of Paintings on the Normal and Pathologic Anatomy and Physiology, Embryology, and Diseases of the Heart*, edited by Fredrick F. Yonkman, Volume 5 of The Ciba Collection of Medical Illustrations, Summit, NJ: Ciba Pharmaceutical Company, 1969.
- Wagner, G. W., *Marriott's Practical Electrocardiography*, 9th ed., Baltimore, MD: Williams & Wilkins, 1994.
- Wellens, H. J., K. I. Lie, and M. J. Janse, (eds.), *The Conduction System of the Heart*, The Hague: Martinus Nijhoff Medical Division, 1978.
- Zipes, D. P., and J. Jalife, (eds.), *Cardiac Electrophysiology: From Cell to Bedside*, 4th ed., Philadelphia, PA: W.B. Saunders and Company, 2004.
- Zipes, D. P., et al., (eds.), *Braunwald's Heart Disease*, 7th ed., Oxford, U.K.: Elsevier, 2004.